



PATIENT

Taffy McAulay

SPECIES

Canine

BREED

Miniature Poodle

SEX

Female Spayed

AGE

10.7 years

WEIGHT

20.2lbs

INTERPRETED BY

Maggie Machen Lamy,
DVM, DACVIM
(Cardiology)

IMAGING PERFORMED BY

B. Barnes, DVM

HOSPITAL NAME

Westview Veterinary
Hospital

REFERRING VET

Dr. Barnes

INVOICE

29564

DATE

3/13/23

PRESENTING CLINICAL SIGNS

History: Recheck echo. Grade 3/6 heart murmur. Doing well. BP: 209mmHg. Sedated with Ace 0.15mg and Torb 1mg IV.

-Current medications: Pimobendan 2.5mg BID.

-Pertinent previous echo findings (9/2022 MML): Moderate MR, moderate LAE, borderline LVE, mild TR: 2.7m/s. LA: 2.8, LV: 2.8.

ECHOCARDIOGRAM FINDINGS

2D, m-mode, color flow and doppler imaging is available. Diffuse thickening of mitral valve leaflets (anterior>posterior) with minimal prolapse into the left atrial lumen. Moderate eccentric mitral regurgitation with moderate left atrial dilation. Normal MR velocity. Borderline LV dilation with adequate myocardial function. The tricuspid valve appears mildly thickened with mild tricuspid regurgitation. Normal TR velocity. Normal right atrial and ventricular diameter. The pulmonic and aortic valves are normal in morphology and mobility. Normal pulmonic and aortic outflow velocities. No aortic and trace pulmonic insufficiency. No pericardial or pleural effusion noted. No cardiac tumors observed.

CARDIAC CHART

CANINE CARDIAC PARAMETERS	MR VMAX (m/s)	TR VMAX (m/s)	LA/AO (Boon method)	LA/AO (Heart Base; Swe)	FS (%)	EF (%)	EPSS (cm)
NORMAL PARAMETER	4.5-5.5	<2.7	1.3	<1.6	28-40	40-100	<0.6
PATIENT	4.9	2.5	1.6	1.75	53	85	NM
CANINE CARDIAC PARAMETERS	HR (BPM)	AV VMAX (m/s)	PV MAX (m/s)	BODY WEIGHT (kg)	LA 2D short axis Base view (cm)	LVIDd Avg; 2D and m-mode short axis (cm)	LVIDs Avg; 2D and m-mode short axis (cm)
NORMAL PARAMETER	50-100	0.7-1.7	0.7-1.6	BELOW	BELOW	BELOW	BELOW
PATIENT	NM	1.5	0.9	9.2	2.4	3.1	1.4
*Normal chamber parameters expressed as a mean value (SD)				3	1.27 (5.3)	2.46 (2.46)	1.36 (5.5)
BODY WEIGHT DEPENDENT PARAMETERS				5	1.40 (4.5)	2.74 (5.2)	1.60 (4.7)
<i>*Note: All measurements based upon multi-modal images and methods. An average value is reported.</i>				10	1.50 (3.8)	3.27 (3.5)	2.06 (3.1)
				15	1.83 (2.0)	3.71 (2.4)	2.43 (2.1)
				20	2.02 (1.9)	4.14 (2.2)	2.80 (2.0)
				25	2.18 (2.4)	4.48 (2.9)	3.10 (2.5)
				30	2.33 (3.3)	4.83 (3.9)	3.39 (3.4)
				35	2.48 (4.3)	5.17 (5.0)	3.69 (4.5)
				40	2.62 (5.2)	5.48 (6.1)	3.96 (5.4)
				50	2.88 (7.1)	6.07 (8.3)	4.46 (7.4)

INTERPRETATION OF THE FINDINGS & FURTHER RECOMMENDATIONS

Unchanged structural disease is identified in this study. Moderate mitral and mild tricuspid regurgitation are unchanged with stable left and right heart dimensions. Pulmonary pressures measure normal today and no additional issues are identified.

Given these findings, reasonable to continue Pimobendan going forward. No additional medications are warranted. Assessment of progression in the future will help predict long term outcome, however prognosis is guarded at this stage (B2).



PATIENT

Taffy McAulay

SPECIES

Canine

BREED

Miniature Poodle

SEX

Female Spayed

AGE

10.7 years

WEIGHT

20.2lbs

INTERPRETED BY

Maggie Machen Lamy,
DVM, DACVIM
(Cardiology)

IMAGING PERFORMED BY

B. Barnes, DVM

HOSPITAL NAME

Westview Veterinary
Hospital

REFERRING VET

Dr. Barnes

INVOICE

29564

DATE

3/13/23

The reported blood pressure is elevated and should be reassessed for accuracy particularly given no reported clinical signs of severe hypertension (retinal changes, etc.) or evidence of LVH on echo. Ideally obtain serial measurements in a controlled, low stress environment and continue until 3 consecutive readings plateau within 5mmHg of variability. If persistently >180mmHg despite a relatively calm demeanor, recommend institution of amlodipine to effect. Additionally, if deemed accurate, screening for predisposing underlying causes of SHT is recommended (Cushing's, PLN, adrenal tumor, etc.), as primary disease is relatively uncommon and a rule out diagnosis.

Omega fatty acid supplementation and mild salt restriction may also be of some long-term benefit. Monitor for development of a progressive cough, labored breathing, exercise intolerance or collapse episodes.

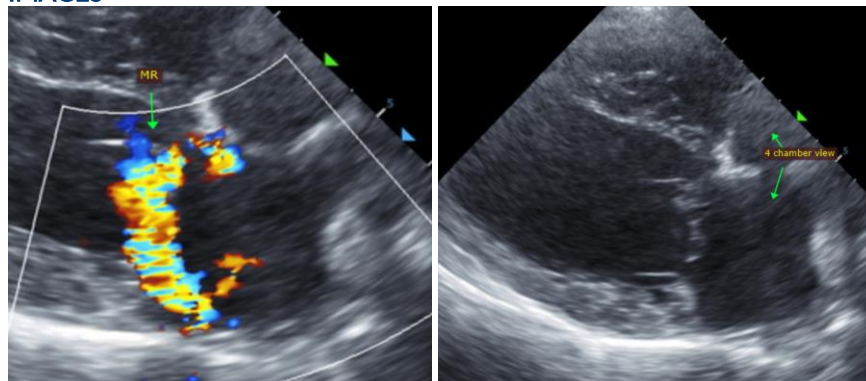
Anesthetic risk is considered mildly elevated. Cardiac protective drug choices (opioid/benzodiazepine premedication, Propofol or alfaxalone induction, iso or sevo gas) are recommended. Monitor for arrhythmias, hypotension, and hypoxia both intra and post-operatively and intervene as necessary. Judicious IV fluid rates are recommended to avoid fluid overload. Avoid heart rate stimulating drugs such as atropine unless clinically indicated.

PLAN

Reassess BP as discussed. Continue Pimobendan 0.25-0.3mg/kg PO q12h.

Recommend monitor for progression with a recheck echocardiogram in 6 months, sooner if any development of clinical signs.

IMAGES



The information and recommendations provided are based on the images presented by the referring veterinarian. No evaluation can be communicated regarding pathology that was not visible in the image/video clips provided.

Thank you for this referral. This report was generated using transcription software, and minor dictation errors may be present. If the clinical or image interpretation does not parallel your findings or if I can be of any further assistance, please contact me.

Maggie Machen Lamy, DVM
Diplomate of the American College of Veterinary Internal Medicine (Cardiology)
info@sonopath.com